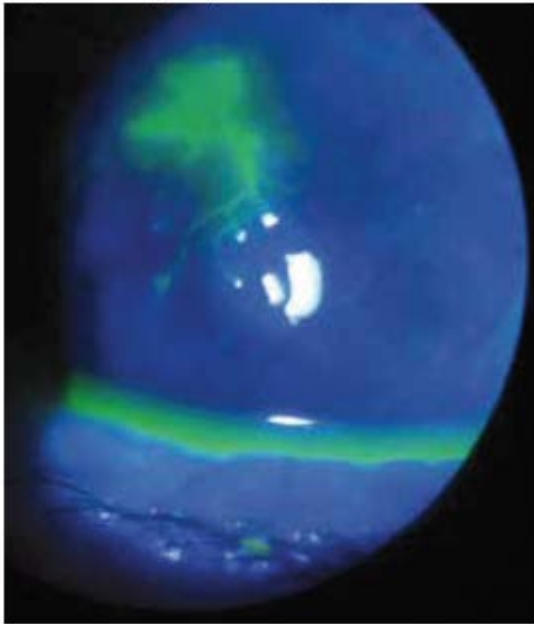


Case study

A 43 year old male presents to you with a red, painful, tearing right eye. His symptoms have been present for one week's duration. He describes photophobia (light sensitivity) and says his vision is blurry. He was seen at another clinic after two days of symptoms and was given topical polysporin (antibiotic) eye drops. Despite using the eye drops for five days, he has had no improvement in his symptoms. The man has no significant ocular past history.

Figure 1. Image of patient's right cornea



Right eye with fluorescein dye under a cobalt blue light.

Questions

Question 1

What is your differential diagnosis? What additional history will help make a definitive diagnosis?

Question 2

How would you examine this patient?

Question 3

What is your diagnosis? How would you treat this patient?

Question 4

What important lessons can be learned from this case?

